

# An Investigation into the Biochemical, Hematological, and Histopathological effects of *Glyphaea brevis* Extracts in Albino rats: Toxicological Appraisal

Ngozi M Uzoekwe <sup>1</sup>, Ikechukwu P Ejidike <sup>2\*</sup>, Mark E Ukhun <sup>3</sup>

<sup>1</sup>Department of Physical Sciences, Benson Idahosa University, Okha, Benin City, Nigeria

<sup>2</sup>Department of Chemical Sciences, Anchor University, Ayobo, Lagos, Nigeria

<sup>3</sup>Department of Chemistry, University of Benin, Benin-City, Nigeria

**Corresponding Author:** Ikechukwu P Ejidike, Department of Chemical Sciences, Anchor University, Ayobo, Lagos, Nigeria.

Email: [iejidike@aui.edu.ng](mailto:iejidike@aui.edu.ng)

Received July 11, 2020; Accepted August 05, 2020; Online Published December 20, 2020

## Abstract

**Introduction:** Drugs from the plants are easily available, less expensive, safe, and efficient and rarely have side effects. *Glyphaea brevis* leaf decoction is reported to be the potent treatment of sexually transmitted infections, abortifacient, ecboic, and antiemetic, in eye treatment, liver problems and nasopharyngeal infections.

**Methods:** The aqueous, ethanolic and methanolic extracts of *Glyphaea brevis* sample were administered to the rats orally once daily at a dose of 250, 500 and 750 mg/kg, body weight for 30 days (on short-term effect) and 60 days (long-term effect). The hematological, biochemical parameters and histopathological examination were studied in the rats.

**Results:** There was a significant difference within the hematological profile of the studied rats for all doses of the methanolic extracts of *G. brevis* ( $p < 0.05$ ). The oxygen-carrying capacity of the blood and amount of oxygen delivered to the tissues of the rats had increased following extract administration. Alanine aminotransferase (ALT), Aspartate aminotransferase (AST) and Alkaline phosphatase (ALP) levels of the albino rats at all dosage administered were statistically significant compared to the control. Histopathological examination showed kupffer cell activation in the liver, normal histology of the kidney and tubules, no signs of glomeronephritis, and mild coronary vascular congestion of the heart.

**Conclusion:** It is proposed that *G. brevis* plant extract has a function of raising White blood cells WBC levels within a normal range such that it can efficiently and effectively fight infections. Treatment with the extracts suggested no impairment of normal kidney functions, thus could be considered as a natural product in the management of diseases.

**Keywords:** *Glyphaea brevis*, Histopathological, Medicinal Plant, Biochemical, Toxicity, Hematological, Albino Rats

## Introduction

The plant kingdom is a treasure house of potential drugs and in the recent years there has been an increasing awareness about the importance of medicinal plants. Drugs from plants are easily available, less expensive, safe, and efficient and rarely have side effects.<sup>1,2</sup> The plants which have been selected for medicinal use over thousands of years constitute the most obvious choice of examining the current search for therapeutically effective new drugs such as anticancer drugs,<sup>3,4</sup> antimicrobial drugs, and anti-hepatotoxic compounds.<sup>1,5</sup> According to World Health Organization (WHO), medicinal plants would be the best source to obtain a variety of drugs. About 80% of individuals from developed countries use traditional medicines, which have compounds derived from medicinal plants.<sup>1,3,4,6</sup> The presence of phytochemical compounds in medicinal plants has been reported.<sup>1,7</sup> Despite these points, comprehensive studies especially, on the phytochemicals and proximate potentials, medical effect on human and animals, are scanty. Therefore, there is a need for such plants to be investigated in order to better understand their properties, safety, and

efficacy.<sup>2,5,8-10</sup>

*Glyphaea brevis* is a spreading shrub, climber or small tree up to 8m high. It is very common in the undergrowth of closed forests, secondary jungles and on river-banks, lowlands to sub-mountains and widespread in tropical Africa. It is widely distributed in Africa.<sup>10</sup> The twigs of *G. brevis* are chewed to clean teeth. *G. brevis* of the family tiliaceae are herbs, shrubs and trees, which are mostly found in tropical regions. They are tap rooted with tall and erect stems. The flowers are regular, bisexual or hypogenous; the leaves are stipulate, alternate, simple, entire or toothed<sup>11</sup> and put into various therapeutic uses such as treatment of hepatitis and poisoning, anticonvulsant, antiallergic and antiarthritic properties.<sup>12,13</sup> *G. brevis* possess antioxidant properties which are related to the therapeutic activities of the plant.<sup>9-11,14</sup> Plants constitute highly available and low-cost sources of antioxidants. *G. brevis* (Spreng), it is popularly called Aloanyasi (Igbo) or Atori (Yoruba). It has been reported to have multiple physiological and pharmacological activities. It is used in the treatment of sleeping sickness and as aphrodisiac, as an anti-inflammatory, antioxidant,

antibacterial in the treatment of eye infection and in gum cleaning. It is also reported to be effective in the treatment of impotency.<sup>9,10,12,13</sup> It has carminative effects and is used as an anticonvulsant, especially in children, where it is either used singly or in combination with other herbs.<sup>12</sup>

Despite these comprehensive studies especially on the phytochemical potentials, there has not been many studies on the medical effects on human and animals. This study aimed at preparing various crude extracts using different

solvent polarities to quantitatively evaluate the phytochemical constituents of the leaves of *Glyphaea brevis*. Extracts of the plants samples were administered to experimental animals (albino rats) so as to assess the medical effect using haematological and biochemical parameters of the blood samples of these experimental animals. Finally, the histopathological parameter of four essential organs (heart, spleen, liver and kidney) were evaluated to ascertain the benefits and toxicity of the plants bioactive compounds.



Figure 1. Plant parts of *Glyphaea brevis*

## Materials and Methods

### Chemicals and Apparatus

All chemicals and reagents were of analytical grades and were obtained from Sigma-Adrich (St Louis, USA). Water bath, spectrophotometer, test tubes, test-tube rack, metal cage, syringe, cotton wool, weighing balance, universal containers, ethylenediaminetetraacetic acid (EDTA) bottle, heparinized bottle, plain container, fridge, foil paper, spatula, dissecting set, centrifuge, micropipette, the biochemical kits. Serum Alanine Transaminase (ALT), Aspartate Transaminase (AST), Alanine Phosphatase (ALP) and serum total protein were estimated colourimetrically using Randox reagent enzyme kit.

### Plant Material Collection and Extraction

Fresh mature leaves of *Glyphaea brevis* were collected from bushes along the Nigerian Institute for Oil Palm Research (NIFOR) road close to Benin City. Identification and authentication of the plant leaves were carried at the Herbarium Section of the Plant Biology and Biotechnology Department, University of Benin, Benin, Nigeria by Mr. Sunny Akamuaguna.

Before the extraction, leaf samples collected from the indicated source were air-dried and grounded into a powder using a blender. Subsequently, known weights of the sample (6000 g) was extracted with 7.5 L of each of the solvents, filtered and evaporated using a rotary evaporator. This was

followed by freeze-drying which now yielded solid extract of the leaves.

### Phytochemical Screening of the Extracts

Phytochemical screening was performed using reported procedures in the literatures with little modifications.<sup>1,4,6,7,11,15-17</sup>

### Animal studies

Albino rats each weighing between 120 – 140 g were used in the studies. They were obtained from the disease-free stock of the Animal Holding Unit of the Department of Biological Sciences, University of Ibadan, Nigeria. The animals were housed in metal cages lined with wood shavings under standard laboratory conditions of temperature and relative humidity with a 12 h light-dark cycle and adequate ventilation. The rats were fed *ad libitum* on water and growers. The animals were allowed to acclimatized for one week. There was daily changing of feed, water and cleaning of the cage.

### Experimental Design

The rats were divided into five groups with 21 rats in each. Groups 1, 2 and 3 were administered orally with various extracts of *Glyphaea brevis* at doses of 250 mg/kg, 500 mg/kg and 750 mg/kg/body weight respectively. The 4th and 5th groups served as the control. The extracts were administered daily through oral route for 60 days.

### Collection and preparation of blood, serum and organs

At the end of the treatment era, the rats were sacrificed, blood was collected from the heart by cardiac puncture and were placed into two different EDTA and lithium heparin tubes for haematological and biochemical tests. Different organs were dissected out and placed in formalin for histology. Lithium heparin tube with serum was centrifuged for 10 mins at 3000 rpm on a bench centrifuge. The plasma was collected for the biochemical analysis.<sup>2,18,19</sup>

### Haematological Assay

The haematological assay was evaluated with an auto-reader PC 210N Erma (Tokyo, Japan). The blood in the EDTA container was used for full blood count which included White Blood Cell count (WBC), Red Blood Cell count (RBC), Haematocrit Count (HCT), Haemoglobin (Hgb) and WBC differentials as described in the literature.<sup>2</sup>

### Analysis of Biochemical Parameters

The ALT, AST and ALP were estimated colourimetrically using Randox reagent enzyme kit based on the previous reported methods.<sup>2,20</sup> The obtained absorbance values were then converted to concentrations using the Randox kit conversion table.

### Calculation

The activity of AST and ALT in the serum samples were extrapolated from a reference standard curve (standards provided in the Randox reagent kit), while ALP activity in IU/L was calculated using the formula:  $IU/L = (\text{Absorbance of sample} / \text{Absorbance of standard}) \times \text{Standard concentration (50)}$ .

### Histopathological examination

Kidney, heart, spleen and liver were embedded in formalin, sectioned at 5 $\mu$  and stained with haematoxylin and eosin. Detailed microscopic examination of the organ section was carried out for both control and test groups. Also, photomicrographs (magnification x400 and x100) were obtained.

### Statistical Analysis

Data obtained from this study were expressed as mean value  $\pm$  standard deviation. Differences among and between means of control and tested groups were determined by One-way ANOVA using Statistical Package for Social Sciences (SPSS).

## Results

### Qualitative Phytochemical Screening of *Glyphaea brevis* Leave Extracts

The phytochemical screening of the aqueous, ethanol and methanol leaf extracts of *Glyphaea brevis* revealed the presence of alkaloids, flavonoids, tannins, proteins, saponins, steroids and a decline in sugar.

### Haematological Effects

The aqueous, ethanolic and methanolic extracts of *Glyphaea brevis* sample were administered to albino rats, in order to investigate any haematological effects in the rats. The results are presented in the following Tables 1-3. There was a significant difference within the haematological profile (WBC, RBC, haemoglobin, platelet, haematocrit, lymphocyte and monocyte) of the studied rats for all doses of the methanolic extracts of *G. brevis* ( $p < 0.05$ ). However, the obtained values were within normal levels. The results showed no deleterious effects on blood cell counts and haemoglobin content thereby suggesting that it had no toxic effect on the blood system. All values for treated groups were within the normal range. Therefore, it is proposed that *G. brevis* plant extract has a function of raising WBC levels within a normal range such that it can efficiently and effectively fight infections. In addition, the oxygen-carrying capacity of the blood and amount of oxygen delivered to the tissues of the rats had increased following extract administration since RBC and HGB are very important in oxygen uptake and transport cycle.

**Table 1.** Haematological effects in albino rats administered aqueous leaf extract of *Glyphaea brevis* over a period of 30 days.

Parameters	Control	250 mg/kg	Dosages	
	(Undosed)		500 mg/kg	750 mg/kg
WBC (10 <sup>3</sup> / $\mu$ L)	10.85 $\pm$ 3.89	13.30 $\pm$ 3.08	8.70 $\pm$ 0.40	6.25 $\pm$ 0.35
Lymphocyte (%)	6.85 $\pm$ 1.77	5.85 $\pm$ 0.78	5.60 $\pm$ 1.41	3.65 $\pm$ 0.21
RBC (Ml/mm <sup>3</sup> )	6.42 $\pm$ 0.57	6.40 $\pm$ 0.60	6.93 $\pm$ 0.08	6.92 $\pm$ 0.04
HGB (g/dl)	14.35 $\pm$ 0.92	14.15 $\pm$ 0.71	15.15 $\pm$ 0.07	14.99 $\pm$ 0.02
Platelet (10 <sup>3</sup> / $\mu$ L)	773.00 $\pm$ 20.81	662.50 $\pm$ 85.56 <sup>a</sup>	796.00 $\pm$ 12.41	703.00 $\pm$ 13.14 <sup>a</sup>
Haematocrit (%)	41.35 $\pm$ 3.18	42.30 $\pm$ 0.85	43.80 $\pm$ 0.20	42.3 $\pm$ 0.57 <sup>a</sup>
Monocyte (%)	1.15 $\pm$ 0.49	1.20 $\pm$ 0.28	1.40 $\pm$ 0.41	8.75 $\pm$ 0.21

<sup>a</sup>= statistically significantly different from the control at  $p < 0.05$

WBC = White Blood Cell, RBC = Red Blood Cell, HGB = Haemoglobin

**Table 2.** Haematological effects in albino rats administered ethanol leaf extract of *Glyphaea brevis* over a period of 30 days.

Parameters	Control (Undosed)	250 mg/kg	Dosages 500 mg/kg	750 mg/kg
WBC ( $10^3/\mu\text{L}$ )	12.40±0.01	7.25 ± 0.07 <sup>a</sup>	9.60±1.10 <sup>a</sup>	8.64 ± 0.05 <sup>a</sup>
Lymphocyte (%)	7.40±1.41	4.40 ± 0.14 <sup>a</sup>	5.35±0.07 <sup>a</sup>	6.35 ± 0.07 <sup>a</sup>
RBC (Ml/mm <sup>3</sup> )	6.67±1.48	6.87 ± 0.11	6.30±0.35	6.52 ± 0.64
HGB (g/dl)	14.35±0.21	16.30 ± 0.28 <sup>a</sup>	14.22±0.16	13.35 ± 0.21
Platelet ( $10^3/\mu\text{L}$ )	647.50±0.17	415.50 ± 2.12 <sup>a</sup>	602.25±0.35 <sup>a</sup>	753.50 ± 0.52 <sup>a</sup>
Haematocrit (%)	39.65±0.49	44.95 ± 0.21 <sup>a</sup>	38.90±0.14	38.45 ± 0.03
Monocyte (%)	1.63±0.04	0.95 ± 0.07 <sup>a</sup>	11.64±0.19 <sup>a</sup>	1.45 ± 0.04

<sup>a</sup>= statistically significantly different from the control at  $p < 0.05$

WBC = White Blood Cell, RBC = Red Blood Cell, HGB = Haemoglobin

**Table 3.** Haematological effects in albino rats administered methanol leaf extract of *Glyphaea brevis* over a period of 30 days.

Parameters	Control (Undosed)	250 mg/kg	Dosages 500 mg/kg	750 mg/kg
WBC ( $10^3/\mu\text{L}$ )	5.65±0.07	12.55±0.21 <sup>a</sup>	6.60±0.14 <sup>a</sup>	10.75±0.35 <sup>a</sup>
Lymphocyte (%)	3.25±0.02	1.35±0.12 <sup>a</sup>	3.45±0.03	5.98±0.04 <sup>a</sup>
RBC (Ml/mm <sup>3</sup> )	5.75±0.09	5.54±0.06	6.55±0.01	6.93±0.10
HGB (g/dl)	15.30±0.28	14.75±0.35	17.85±0.07 <sup>a</sup>	15.15±0.06
Platelet ( $10^3/\mu\text{L}$ )	411.50±0.71	414.00±4.24	678.50±0.17 <sup>a</sup>	856.50±2.12 <sup>a</sup>
Haematocrit (%)	42.35±0.21	39.80±0.50 <sup>a</sup>	48.55±0.64 <sup>a</sup>	39.27±0.40 <sup>a</sup>
Monocyte (%)	0.80±0.14	1.45±0.12	0.89±0.04	1.45±0.05

<sup>a</sup>= statistically significantly different from the control at  $p < 0.05$

WBC = White Blood Cell, RBC = Red Blood Cell, HGB = Haemoglobin

### Biochemical effects on albino rats administered various extracts of *G. brevis*

The aqueous, ethanolic and methanolic extracts of the *Glyphaea brevis* at 250, 500 and 750 mg/kg dosage were administered to the albino rats based on the short-term effect (30 days) and long-term effect (60 days) of the plant extracts in order to the biochemical parameters (ALT, AST and ALP). The results of these tests are presented in the following Tables 4-9.

The levels of ALT of the albino rats which were administered with 250 and 500 mg/kg *G. brevis*, were significantly decreased but 750 mg/kg dosage did not cause any significant effect (Table 4) at short-term effect (30 days). On the other hand, no significant changes were observed in the levels of AST when 250, 500 and 750 mg/kg dosages of the *G. brevis* aqueous plant extract were administered. Furthermore, at all dosage, *G. brevis* was seen to significantly affect ALP levels in treated albino rats at ( $p < 0.05$ ). Table 5 shows that the levels of ALT, AST and ALP of the albino rats at all dosages (250, 500 and 750 mg/kg) were statistically significant from the control at  $p < 0.05$ . In the long-term effect (60 days) of the plant extracts administration with the

aqueous extracts of *G. brevis*, significant changes in the ALT, AST and ALP levels of the albino rats at all concentrations (250, 500 and 750 mg/kg) were observed compared to the levels of the untreated rats (Table 5).

In Table 6, ALT levels of the albino rats were significantly increased with 250 and 750 mg/kg ethanolic extract of *G. brevis* but the dosage of 500 mg/kg had no significant change. The ALT levels of the albino rats significantly increased with 250 mg/kg ethanolic extract of *G. brevis* while 750 mg/kg increased slightly. This is while, 500 mg/kg had no significant change (Table 7). The AST levels of the albino rats on the other hand had significantly increased when compared to control rats at all concentrations. Meanwhile, the ALP level decreased in all dosages ( $p < 0.05$ ). From Tables 8 and 9, ALT levels of the albino rats had significantly increased when 250, 500 and 750 mg/kg methanolic extract of *G. brevis* was administered. The AST and ALP levels of the albino rats on the other hand had significantly altered when compared to the control rats at all concentrations ( $p < 0.05$ ). By comparing ALT, AST and ALP levels of the albino rats treated for 30 and 60 days, more significant changes were observed in the biochemical properties for the albino rats treated for 60 days.

**Table 4.** Levels of biochemical makers of liver injury in albino rats administered with aqueous leaf extracts of *G. brevis* – (Day 30)

Biochemical parameters (IU/L)	Control (Undosed)	250 mg/kg	Dosages 500 mg/kg	750 mg/kg
Alanine aminotransferases (ALT)	8.54±0.48	4.32±0.28 <sup>a</sup>	4.30±0.32 <sup>a</sup>	8.43±0.22
Aspartate aminotransferases (AST)	27.90±36.08	27.31±0.27	14.42±0.38 <sup>a</sup>	52.13±0.12 <sup>a</sup>
Alkaline phosphatase (ALP)	176.68±0.21	84.09±0.94 <sup>a</sup>	154.51±0.19 <sup>a</sup>	28.88±37.13 <sup>a</sup>

<sup>a</sup>= statistically significantly different from the control at  $p < 0.05$



**Table 5.** Levels of biochemical makers of liver injury in albino rats administered with aqueous leaf extracts of *G. brevis* – (Day 60)

Biochemical parameters (IU/L)	Control (Undosed)	250 mg/kg	Dosages 500 mg/kg	750 mg/kg
Alanine aminotransferase(ALT)	8.78±0.21	4.21±0.22 <sup>a</sup>	4.09±0.12 <sup>a</sup>	4.23±0.29 <sup>a</sup>
Aspartate aminotransferase (AST)	7.13±0.13	39.21±0.1 <sup>a</sup>	7.53±0.50 <sup>a</sup>	16.48±0.4 <sup>a</sup>
Alkaline phosphatase (ALP)	176.68±0.21	52.45±0.22 <sup>a</sup>	201.20±0.57 <sup>a</sup>	60.45±0.24 <sup>a</sup>

<sup>a</sup>= statistically significantly different from the control at  $p < 0.05$

**Table 6.** Levels of biochemical makers of liver injury in albino rats administered with ethanolic leaf extracts of *G. brevis* – (Day 30)

Biochemical parameters (IU/L)	Control (Undosed)	250 mg/kg	Dosages 500 mg/kg	750 mg/kg
Alanine aminotransferase (ALT)	3.60±0.18	15.11±0.12 <sup>a</sup>	3.59±0.23	6.49±0.02 <sup>a</sup>
Aspartate aminotransferase AST)	12.33±0.58	49.49±0.46 <sup>a</sup>	43.84±3.33 <sup>a</sup>	19.53±0.17 <sup>a</sup>
Alkaline phosphatase (ALP)	169.95±0.05	46.87±0.86 <sup>a</sup>	21.66±0.38 <sup>a</sup>	55.08±0.09 <sup>a</sup>

<sup>a</sup>= statistically significantly different from the control at  $p < 0.05$

**Table 7.** Levels of biochemical makers of liver injury in albino rats administered with ethanolic leaf extract of *G. brevis* – (Day 60)

Biochemical parameters (IU/L)	Control (Undosed)	250 mg/kg	Dosages 500 mg/kg	750 mg/kg
Alanine aminotransferase (ALT)	4.20±0.20	15.92±0.45 <sup>a</sup>	3.20±0.12 <sup>a</sup>	6.31±0.33 <sup>a</sup>
Aspartate aminotransferase (AST)	9.98±4.85	49.29±0.53 <sup>a</sup>	45.14±0.17 <sup>a</sup>	19.72±0.26
Alkaline phosphatase (ALP)	168.00±1.00	47.10±0.40 <sup>a</sup>	21.22±0.20 <sup>a</sup>	55.07±0.08 <sup>a</sup>

<sup>a</sup>= statistically significantly different from the control at  $p < 0.05$

**Table 8.** Level of biochemical makers of liver injury in albino rats administered with methanolic leaf extract of *G. brevis* – (Day 30)

Biochemical parameters (IU/L)	Control (Undosed)	250 mg/kg	Dosages 500 mg/kg	750 mg/kg
Alanine aminotransferase (ALT)	3.11±0.11	89.50±0.50 <sup>a</sup>	53.02±0.24 <sup>a</sup>	41.39±0.55 <sup>a</sup>
Aspartate aminotransferase (AST)	2.30±0.34	68.26±0.23 <sup>a</sup>	23.27±0.28 <sup>a</sup>	11.23±0.32 <sup>a</sup>
Alkaline phosphatase (ALP)	170.02±0.14	132.42±0.39 <sup>a</sup>	103.34±0.30 <sup>a</sup>	193.29±0.13 <sup>a</sup>

<sup>a</sup>= statistically significantly different from the control at  $p < 0.05$

**Table 9.** Levels of biochemical makers of liver injury in albino rats administered with methanolic leaf extracts of *G. brevis* – (Day 60)

Biochemical parameters (IU/L)	Control (Undosed)	250 mg/kg	Dosages 500 mg/kg	750 mg/kg
Alanine aminotransferase (ALT)	3.62±0.14	60.95±0.49 <sup>a</sup>	51.01±0.76 <sup>a</sup>	22.64±0.13 <sup>a</sup>
Aspartate aminotransferase (AST)	2.70±0.10	5.10±0.10 <sup>a</sup>	4.03±0.06 <sup>a</sup>	6.55±0.05 <sup>a</sup>
Alkaline phosphatase (ALP)	168.25±0.66	103.60±0.53 <sup>a</sup>	98.31±0.37 <sup>a</sup>	102.23±1.17 <sup>a</sup>

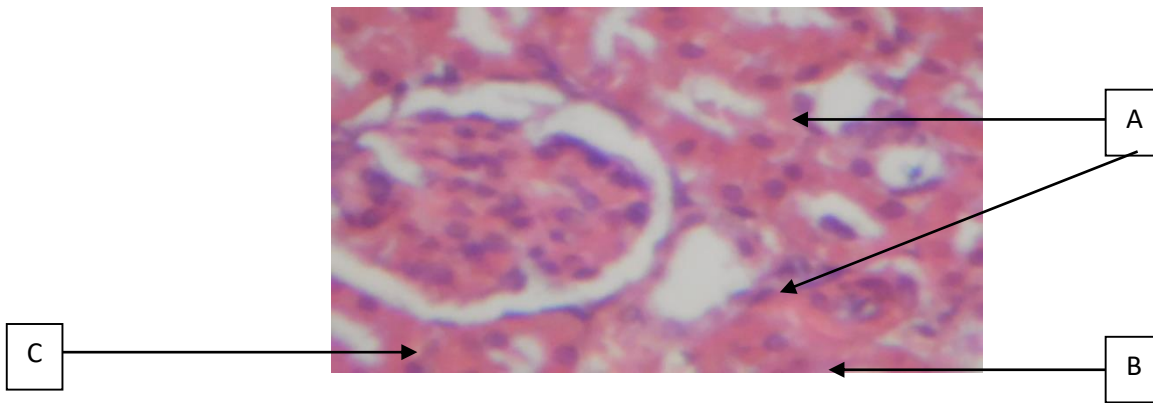
<sup>a</sup>= statistically significantly different from the control at  $p < 0.05$

### Morphological and histopathological examinations

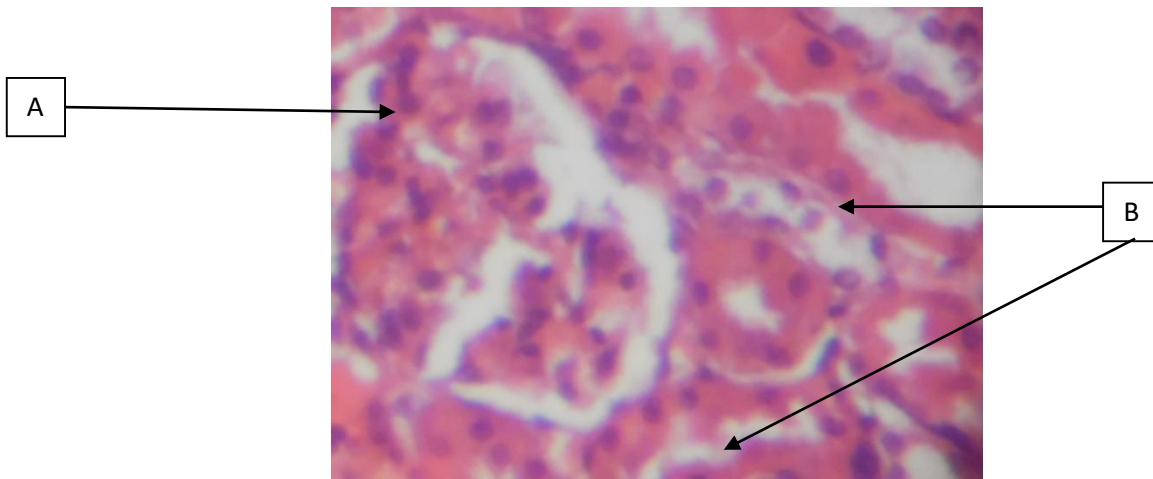
Histopathological examinations of the kidney, heart, spleen, and liver showed evident changes and injuries in normal control and albino rats treated with aqueous, methanolic and ethanolic extracts of *Glyphaea brevis*. The treatment of albino rats in groups with 250 mg/kg, 500 mg/kg and 750 mg/kg dosage of the extract produced observable changes and injuries in the various organs such as the liver, kidney, heart, and the spleen. Rat control kidney photomicrograph showed A-tubules, B-interstitial space and C-glomerulus (Figure 2a); treatment of rat kidney with 250 mg/kg, 500 mg/kg and 750 mg/kg aqueous, methanol, and ethanol extracts of *G. brevis*, A-normal glomerulus and B-tubules was observed, no sign of glomeronephritis (inflammation and damage of filtering component of the kidney) (Figures 2b and S2a-e). The photomicrograph of rat heart showed A-bundles of myocardial fibres, B-coronary

artery and C-interstitial space (Figure 3a); treatment of the rat heart with 250 mg/kg, 500 mg/kg and 750 mg/kg aqueous, methanol, and ethanol extracts of *G. brevis*, A-normal of myocardial architecture and B-normal to mild coronary congestion of the heart was observed. (Figure 3b and S3a-h).

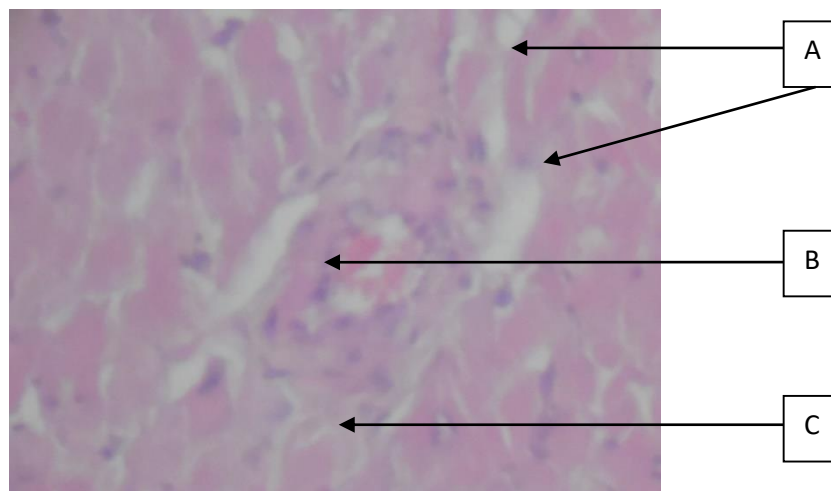
The albino rats spleen control photomicrograph displayed A-white pulp and B-red pulp (Figure 4a); after treatment of the rat spleen with 250 mg/kg, 500 mg/kg and 750 mg/kg aqueous, methanol, and ethanol extracts of *G. brevis*, A-normal follicular architectures were observed (Figure 4b and S4a-h). The control photomicrograph of rat liver showed A-Hepatocytes, B-sinusoids and C-central vein (Figure 5a); after treatment with 250 mg/kg, 500 mg/kg and 750 mg/kg aqueous, methanol, and ethanol extracts of *G. brevis*, rat liver showed mild to moderate kupffer cell activation (Figure 5b and S5a-g). Other Photomicrographs of *Glyphaea brevis* organ groups are presented in the supplementary files.



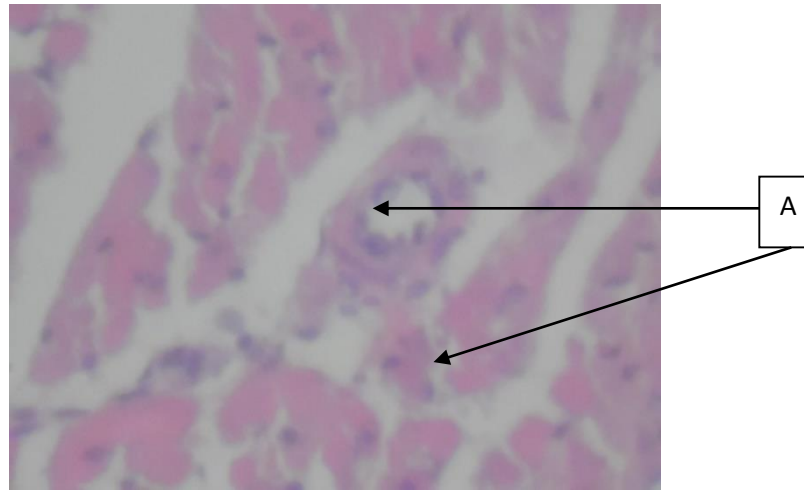
**Figure 2a.** Kidney section of normal control rat showing A, tubules, B, interstitial space and C, glomerulus (H&E x 100)



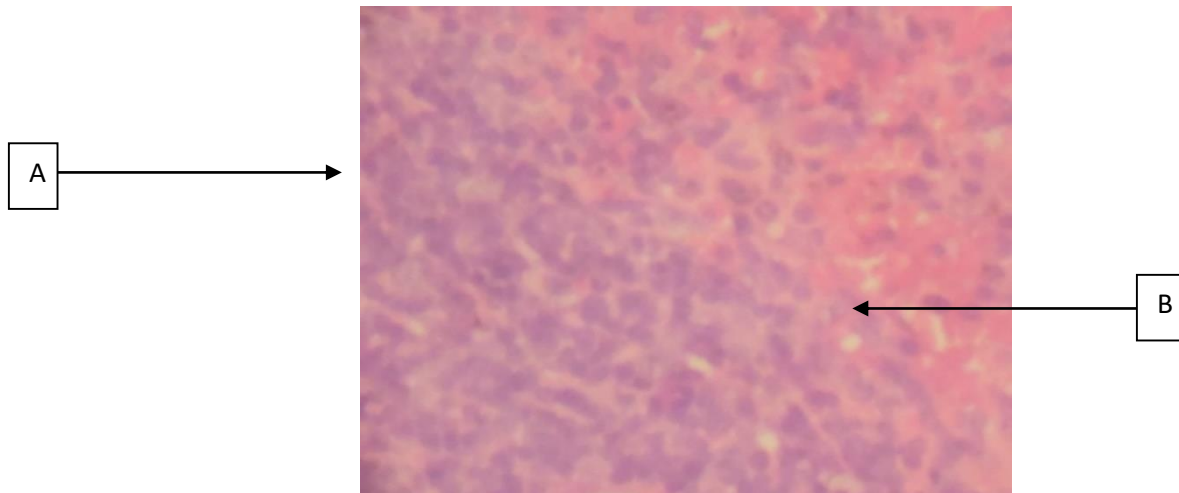
**Figure 2b.** Rat kidney treated with 250 mg/kg aqueous extract of *G. brevis* showing A, normal glomerulus and B, tubules (H&E x 100)



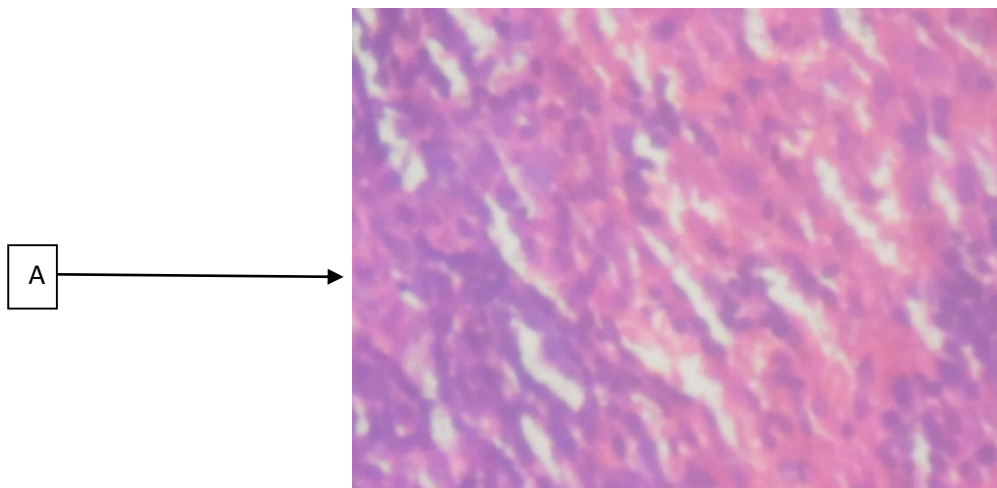
**Figure 3a.** Heart section of normal control rat showing A, bundles of myocardial fibres, B, coronary artery and C, interstitial space (H&E x 100)



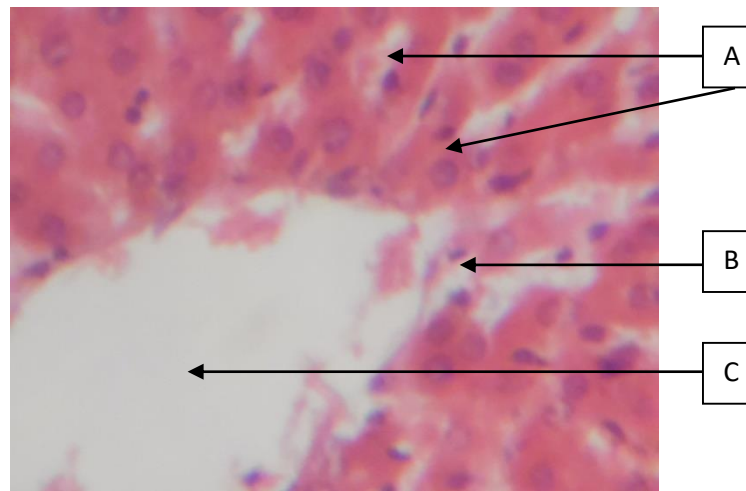
**Figure 3b.** Rat heart treated with 250 mg/kg aqueous extract *G. brevis* showing A, normal myocardial architecture (H&E x 100)



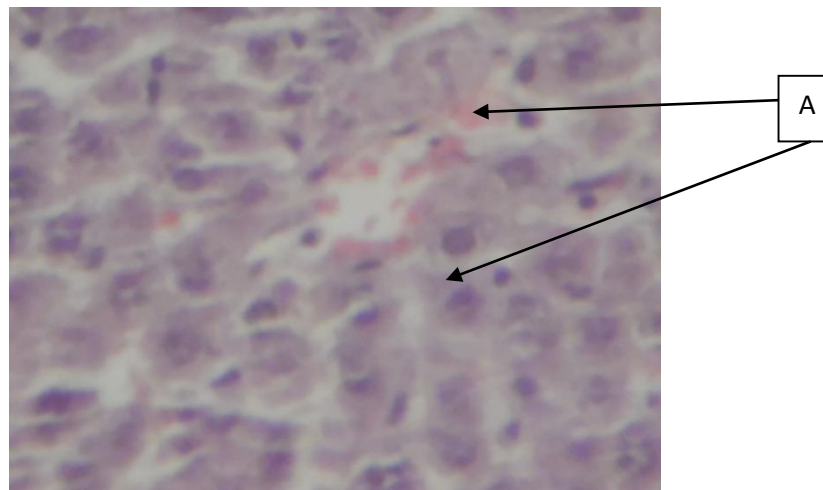
**Figure 4a.** Rat spleen section of normal control showing composed of A, white pulp and B, red pulp (H&E x 100)



**Figure 4b.** Rat spleen treated with 250 mg/kg aqueous extract of *G. brevis* showing A, normal follicular architecture (H&E x 100)



**Figure 5a.** Liver section of normal control rat showing A, Hepatocytes, B, sinusoids and C, central vein (H&E x 100)



**Figure 5b.** Rat liver treated with 250 mg/kg aqueous *G. brevis* showing A, mild kupffer cell activation (H&E x 100)

## Discussion

### Phytochemicals

Plants are rich in a wide variety of secondary metabolites such as tannins, terpenoids, alkaloids and flavonoids.<sup>1,4,9,10,17,21</sup> Qualitative analysis of phytochemicals remains vital in plants medicinal and pharmacological studies.<sup>6,15</sup> Phytochemical screening of *Glyphaea brevis* leaf revealed the presence of alkaloids, flavonoids, steroids, saponins, reducing sugar, protein and tannins in the plant extracts. These phytochemicals exhibit various pharmacological and biochemical actions when ingested by animals.<sup>1,4,6,10,15</sup> The results for the qualitative phytochemical screening of *Glyphaea brevis* were in agreement with the study of Ngumah *et al.*<sup>22</sup> and Ojelabi *et al.*<sup>10</sup>.

### Haematological parameters

Ethanol extracts of *Glyphaea brevis* caused a significant decrease in WBC population of the albino rats used in this study, while methanolic extract caused a significant increase in WBC population of the albino rats. The increase and decrease could be as a result of normal immunological reaction to foreign substances in the rat system. Although a significant increase in WBC was observed, there was a significant decrease in platelet concentration and a slight increase in haematocrit concentration at 750 mg/kg dosage when compared to control. Also, the ethanol extract led to an increase in monocyte level at 500 mg/kg dosage and significant decrease in WBC, lymphocyte and platelet levels at 500 and 750 mg/kg dosages. The methanolic extract of the sample increased the concentration of WBC as well as the



lymphocyte, HGB and platelet and slightly decreased RBC levels.

A consistent increase in WBC concentration was observed. White Blood Cells in the body constitute a special system for combating infections and toxic agents. They are the mobile units of the body's protective systems.<sup>23</sup> However, all values for treated groups were within the normal range. Therefore, it is proposed that *Glyphaea brevis* plant extract exhibit a function of raising WBC levels within a normal range in order to efficiently and effectively fight infections. In addition, the oxygen-carrying capacity of the blood and amount of oxygen delivered to the tissues of the rat will increase following extracts administration since RBC and HGB are very important in oxygen uptake and transport cycle. Analysis of blood parameters is relevant to risk evaluation as the changes in the haematological system have a higher predictive value for human toxicity, when the data are translated from animal studies.<sup>2,24</sup> There was a significant difference within the haematological profile (WBC, RBC, haemoglobin, platelet, haematocrit, lymphocyte and monocyte) of the studied rats for all doses of the methanolic extracts of *G. brevis* ( $p < 0.05$ ).

Nevertheless, the obtained values were within normal levels. The obtained data revealed no harmful effects on the blood cell counts and haemoglobin content thus, signifying that there was no toxic effect on blood system by the administered extracts.<sup>24</sup> In the present study, ethanolic leaf extracts of *G. brevis* did not alter haematological parameters outside of the normal range of all doses administered to rats. This revealed the fact that haematological parameters remained within normal range after administration with all doses of ethanolic leaf extracts. These outcomes are similar to earlier reports by previous studies,<sup>25-27</sup> describing the absence of significant effect on the haematological parameters of blood after administration of plant extracts.

### Biochemical Studies

Assessment of liver function can be made by estimating the activities of serum AST, ALT and ALP, where enzymes originally present in the cytoplasm are in higher concentration.<sup>28</sup> However, when there is hepatopathy, these enzymes leak into blood stream, an indication of the degree of liver damage.<sup>23</sup> A raise in the levels of serum transaminase enzymes is an indication of the hepatic impairment in the studied animals.<sup>2</sup> Aminotransferases are liver-specific enzymes, and are considered to be very sensitive and reliable indices for hepatotoxic effects of various compounds. Alkaline Phosphatase (ALP) is a membrane-bound glycoprotein enzyme with a high concentration in sinusoids and endothelium.<sup>29,30</sup> Moreover, ALT is a cytoplasmic enzyme that upsurges in plasma, an indication of damage by toxicants in the liver.<sup>30</sup> The leakage of liver enzymes from the cells into the blood stream leading to a decrease in ALT and

AST levels in the hepatic cells supported by an increase of ALT and AST levels in the serum was as a result of normal membrane permeability disruption and transport function.<sup>24,25,30</sup>

Biochemical results for aqueous extract of *Glyphaea brevis* (for day 30) showed a statistically significant decrease in serum ALT levels and even a greater decrease at day 60, at all investigated concentrations. This observation indicates a healthy liver after extract administration. A similar observation was seen in a study whereby the serum ALT levels were reported to decrease after *Rhinacanthus nasutus* administration.<sup>32</sup> Additionally, it is observed from this study that a significant decrease in serum ALP levels occurred. The decrease in both ALT and ALP shows the hepatoprotective effect of aqueous extract of *G. brevis* which could be attributed to the presence of the antioxidant metabolite in the leaf extract.<sup>10,28</sup> Significantly, elevated levels of ALT and AST in the albino rats 250, 500 and 750 mg/kg ethanolic extract of *G. brevis*, as compared with the untreated often suggest the presence of other medical challenges such as viral hepatitis, diabetes, congestive heart failure, liver damage, bile duct problems, infectious mononucleosis, or myopathy. Therefore, ALT is usually utilized as a way of screening for liver diseases. A choline deficiency may cause a rise in the ALT level. However, an elevated ALT level does not conclusively confirm the presence of a medical issue.

The fluctuation of ALT levels during the day is normal and they could rise in response to vigorous physical exercise.<sup>23,31</sup> Liver injury was characterized by an increased level of mitochondrial enzyme AST and the main elevation of ALT in plasma, reflecting severe tissue injuries.<sup>30</sup> Significantly elevated levels of ALT often suggest the presence of other medical challenges such as viral hepatitis, diabetes, congestive heart failure, liver damage, bile duct problems, infectious mononucleosis, or myopathy. Therefore, ALT is usually utilized as a way of screening for liver diseases. A choline deficiency may cause a rise in ALT level. However, an elevated ALT level does not conclusively confirm the presence of a medical issue. ALT levels fluctuation during the day is normal and they could rise in response to vigorous physical exercise.<sup>23,31</sup> This elevation observed in the albino rats as a result of 250, 500 and 750 mg/kg extracts of *G. brevis* administered could be as a results of choline deficiency.<sup>31</sup>

### Histological effects of *Glyphaea brevis*

Histopathological and morphological studies for the administration of graded doses of aqueous, methanolic and ethanolic extracts of *Glyphaea brevis* on adult rat's kidney revealed tubules, interstitial space and glomerulus. A normal histology of the kidney was observed with no signs of glomeronephritis (inflammation and damage of filtering component of the kidney). Kidney, on the other hand, removes waste products (many of which are toxic) from the

blood and also plays a major role in controlling blood volume, the concentration of ions in the blood and pH of blood.<sup>10,23,28</sup> The kidneys are also involved in the control of RBC production and vitamin D metabolism. The administration of graded doses of aqueous, methanolic and ethanolic extracts of *Glyphaea brevis* on adult rats showed no effect on the liver and kidney. The histopathological results of the liver did not show any fatty change or hepatocytes necrosis just as the control. This explains the normal level of the ALT, ALP and AST.

The histological results of the heart administered with graded doses extracts of *G. brevis* on adult rats induced normal to mild vascular congestion in the heart. A normal bundle of myocardial fibres and normal coronary artery of the heart was observed. After the treatment with 250 and 500 mg/kg aqueous, 500 and 750 mg/kg methanol, and 250 and 500 mg/kg ethanol extracts of *G. brevis*, a normal myocardial architecture of the heart was observed. In the case of rat spleen photomicrographs treated with graded doses of aqueous, methanolic and ethanolic extracts of *G. brevis*, a normal follicular architecture was observed. It was also detected that low a dose (250 mg/kg) of the investigated extracts activated the local immune system of the spleen (follicular activation and sinus histiocytosis).

Liver plays a major role in metabolism and has a number of functions in the body which include glycogen storage, decomposition of RBC, plasma protein synthesis, and hormone production, metabolism of xenobiotic and excretion of waste materials. Most injected agents pass through the liver before entering the general circulation.<sup>24,25,32</sup> Histopathological examination of the liver treated with graded doses of aqueous, methanolic and ethanolic extracts of *G. brevis*, showed a mild kupffer cell activation. Kupffer cells are hepatic macrophages that reside in the lumen of hepatic sinusoids.<sup>23</sup> They become activated in the presence of liver injury and hepatocellular necrosis where they become the source of inflammatory mediators.

However, rises in AST in conjunction with ALT indicate hepatocellular damage. The increase in AST and ALT may indicate liver malfunction caused by the plant extract as the photomicrograph of the liver showed some mild kupffer cell activation at all concentrations and in all the solvent extracts. Liver damage could be confirmed by the changes in the activities of hepatic enzymes in serum or plasma by their increased or decreased synthesis from damaged cells and extra hepatic tissues.<sup>23,31</sup>

## Conclusion

Medicinal plants characterize ample potential basis for therapeutic agents and have been used for decades for the maintenance of health; and treatment and management of microbial infections, viral and parasitic infections, oxidative

stress, diabetics, and cancer. This has provided unlimited opportunities for new drug leads because of the unmatched availability of chemical diversity. From the study, the haematological assessment of the various extracts of the *Glyphaea brevis* have indicated that the levels of WBC, lymphocyte, RBC, HGB, thrombocytes (platelet), haematocrit and monocyte were different from those of untreated rats, clearly indicating medical effects of these extracts. Treatment with the extracts suggested no impairment to normal kidney functions. The extracts showed good number of bioactive compounds in the preliminary phytochemical assay, which could be used in food and therapeutic applications. Additionally, it is observed from this study, that a significant decrease in the serum ALP levels has occurred. The decrease in both ALT and ALP shows the hepatoprotective effect of aqueous extract of *G. brevis* which could be attributed to the presence of the antioxidant metabolite in the leaf extracts. However, significantly elevated levels of ALT and AST in the albino rats treated with dose extracts of *G. brevis* calls for carefulness when using these extracts as an oral medication in a long period of time.

## Ethical guidelines

Internationally standing accepted principles for laboratory animal use and care as contained in the Canadian Council on Animal Care Guidelines and Protocol Review were practiced and fully observed alongside the ethical guidelines governing the use of laboratory animals as laid out by the Committee on Ethics for Medical and Scientific Research, University of Ibadan, Nigeria.

## Conflicts of Interests

The authors declare no potential conflict of interest with respect to the authorship and/or publication of this study.

## Funding/Support

The present study did not receive any precise grant from funding agencies in the public, commercial, or NGOs sectors.

## References

1. Mtunzi FM, Ejidike IP, Matamela T, Dikio ED, Klink MJ. Phytochemical profiling, antioxidant and antibacterial activities of leaf extracts from *Rhus leptodictya*. *Int. J. Pharmacognosy and Phytochem. Res.* 2017; 9: 1090-1099. doi:10.25258/phyto.v9i08.9616
2. Alawode AR, Dauda M, Gbolagade Adegbola A, Babatunde OR. Biochemical and hematological effect of *Cordyla pinnata* following acute and sub-acute exposure to *Rattus norvegicus*. *Iranian Journal of Toxicology.* 2020; 14(1): 43-50.
3. Peteros NP, Uy MM. Antioxidant and cytotoxic activities and phytochemical screening of four Philippines medicinal plants. *Journal of Medicinal Plants Research.* 2010; 4(5): 407-414.
4. Mtunzi FM, Ejidike IP, Ledwaba I, Ahmed A, Pakade VE, Klink MJ, Modise SJ. Solvent-solvent fractionations of *Combretum erythrophyllum* (Burch.) leaf extract: Studies of their

- antibacterial, antifungal, antioxidant and cytotoxicity potentials. *Asian Pacific Journal of Tropical Medicine*. 2017; 10(7): 670-679. doi:10.1016/j.apjtm.2017.07.007
5. Peters JN, Bimenya GS, Ojok IJ, Ochiene J, Ogwal-Okeng JW. Phytochemicals and uses of *Moringa Oleifera* leaves in Uganda, rural communities. *Journal of medicinal Plant Research*. 2011; 4(9): 753-757.
6. Motsumi PT, Qwebani-Ogunleye T, Ejidike IP, Mtunzi FM, Nate Z. Teedia lucida root extracts by ultrasonication and maceration techniques: Phytochemical screening, antimicrobial and antioxidant activity. *Rasayan Journal Chemistry*. 2020; 13(1): 423-433. doi:10.31788/RJC.2020.1315594
7. Sofowora A. *Medicinal plants and traditional medicine in Africa*, 3rd ed., Spectrum Books Limited, Ibadan, Nigeria 2008; pp.199-204.
8. Arunkumar S. and Muthuselvam T. Analysis of phytochemical constituents and antimicrobial activities of aloe Vera L. against clinical pathogens. *World Journal of Agricultural Science*. 2009; 5(5): 572-576.
9. Dickson R, Ekuadzi E, Annan K, Komlaga G. Antibacterial, anti-inflammatory and antioxidant effects of the leaves and stem bark of *Glyphaea brevis* (Spreng) Monachino (Tiliaceae): A comparative study. *Pharmacognosy research*. 2011; 3(6): 166-172. doi:10.4103/0974-8490.85001
10. Ojelabi BA, Areola JO, Babalola OO. Roles of *Glyphaea brevis* (Spreng) extract in cadmium induced hepatocellular damage and oxidative stress in rabbit. *Journal of Biotechnology and Pharmacy Research*. 2012; 3(7): 123-128.
11. Oshomoh EO, Idu M. Phytochemical screening and antimicrobial activity of ethanol and aqueous extracts of stem of *Glyphaea brevis* (spreng.) *Pharmacology Journal*. 2012; 4(33):23-33. doi:10.5530/pj.2012.33.4
12. Ogbonna S, van Staden J, Jager AK, Coker HA. Anticonvulsant effect of *Glyphaea brevis* (Spreng) Morches leaf extracts in mice and preliminary phytochemical tests. *Nigerian Quarterly Journal of Hospital Medicine*. 2003;13(3-4):62-64. doi:10.4314/nqjhm.v13i3-4.12662
13. Obiri DD, Osafo N, Abotsi RE. Antiallergic and antiarthritic effects of stem bark extract of *Glyphaea brevis* (Spreng) monachino (Tiliaceae) in murine models. *ISRN Pharmacology*. 2013; 13: Article ID 874263. doi:10.1155/2013/874263
14. Agbor G, Kuate D, Oben, J. Medicinal plants can be good sources of antioxidants: Case study in Cameroon. *Pakistan Journal of Biological Sciences*. 2007; 10 (4): 537-544. doi:10.3923/pjbs.2007.537.544
15. Chikezie PC, Ibegbulem CO and Mbagwu FN. Bioactive principles from medicinal plants. *Res. J. Phytochem*. 2015; 9: 88-115. doi:10.3923/rjphyto.2015.88.115
16. Khumalo BM, Qwebani-Ogunleye T, Ejidike IP, Mtunzi FM, Pinkoane M. Evaluation of immune booster formulation by traditional health practitioners: Phytochemical, antioxidant and mineral elements studies. *International Journal of Pharma and Bio sciences*. 2018; 9(2): 29-37. doi:10.22376/ijpbs.2018.9.2.p29-37
17. Makanyane DM, Ejidike IP, Ssemakalu CS, Mtunzi FM, Pakade VE, Klink MJ, Lebelo RS. GC-MS analysis and extraction optimization of bioactive compounds from *Pelargonium graveolens* L'Her methanolic extract and their activities as pharmacological agents. *International Research Journal of Pharmacy*. 2019; 10(9): 59-72. doi:10.7897/2230-8407.1009263
18. Amos TN, Bashir L, Saba SE, Saba MA, Mohammed BM, Abdulsalam IH, Josiah GJ. Phytochemicals and acute toxicity profile of aqueous and methanolic extracts of *Crateva adansonii* leaves in Swiss albino rats. *Asian Journal of Biochemistry*. 2015; 10(4): 173-179. doi:10.3923/ajb.2015.173.179
19. Ojo OO, Ajayi SB, Nwaechehu OO, Ejidike IP. GC-MS analysis and attenuation of bleomycin-induced lung fibrosis by fractionated methanolic extract of *Cissampelos Owariensis* in Wistar rats, *Journal of Herbs, Spices & Medicinal Plants*. 2020; 26(2): 155-171. doi:10.1080/10496475.2019.1689541
20. Reitman S, Frankel S. A colorimetric method for the determination of serum glutamate oxaloacetate and pyruvate transaminase. *American Journal of Clinical Pathology*. 1957; 28(8): 56-63. doi:10.1093/ajcp/28.1.56
21. Srivastava J, Chandra H, Nautiyal AR, Kalra SJS. Antimicrobial resistance (AMR) and plant-derived antimicrobials (PDAMs) as an alternative drug line to control infections. *Biotech*. 2014; 4: 451-460. doi:10.1007/s13205-013-0180-y
22. Ngumah C, Ogbulie J, Orji J. Antifungal potencies of leaf extracts of *Glyphaea brevis* and *Spondias mombin* on fungi implicated in dry rot of postharvest yam. *Annals of Food Science and Technology*. 2013; 14 (2): 330-335.
23. Adeleye GS, Nneli R, Nwozor CM, Emesiana MC. Effects of coartem and artesunate on some haematological and biochemical parameters in albino rats. *African Journal of Biomedical Research*. 2012; 15(2): 55-58. doi:10.9790/3008-0465558
24. Ramanathan N, Tan E, Loh LJ, Soh BS, Yap WN. Tocotrienol is a cardioprotective agent against ageing-associated cardiovascular disease and its associated morbidities. *Nutrition & metabolism*. 2018 Dec 1;15(1):6. doi:10.1186/s12986-018-0244-4
25. Amole OO, Izegbu MC, Onakoya JAA, Dada MO. Toxicity studies of the aqueous extract of *Vernonia amygdalina*. *Biomedical Resources*. 2006; 17(5): 39-40.
26. Eleyinmi AF, Sporns P, Bressler DC. Nutritional composition of *Gongronema latifolium* and *Vernonia amygdalina*. *Nutrition Food Science*. 2006; 38: 99-109. doi:10.1108/00346650810862975
27. Mebratu M, Delgado G, Montano CA, Hu SW, Ryter AM, Choi I. Deacetylation of p53 induces Autophagy by suppressing Bmf expression. *The Journal of Cell Biology*. 2013; 201(3): 427-437. doi:10.1083/jcb.201205064
28. Shah MD, Hossain MA. Total flavonoids content and biochemical screening of the leaves of tropical endemic medicinal plant *Merremia borneensis*. *Arabian Journal of Chemistry*, 2014; 7(6): 1034-1038. doi:10.1016/j.arabcj.2010.12.033
29. Anusha B, Nithya V, Vidhya VG. Phytochemical evaluation by GC-MC antihyperglycemic activity of *Mucuna pruriens* on straptozoan induced diabetes in rats. *Journals of Chemistry and Pharmaceutical Research*. 2011; 3(5): 689-696.
30. Yusuf AA, Lawal B, Yusuf MA, Omonije YO, Adejoke AO, Raji FH, Wenawo DL. Free radical scavenging, antimicrobial activities and effect of sub-acute exposure to Nigerian *Xylopiya aethiopia* seed extract on liver and kidneys functional indices of albino rat. *Iranian Journal of Toxicology*. 2018; 12(3): 51-58.
31. Wang L, Rozmahel RF, Amtul Z, Uhrig M, Beyreuther K. Detrimental effects of arachidonic acid and its metabolites in cellular and mouse models of Alzheimer's disease: Structural insight. *Neurobiology of Aging*. 2012; 33 (4): 821-831. doi:10.1016/j.neurobiolaging.2011.07.014
32. Pasupuleti V, Rao K, Madhavi M, Dhananjaya N, Siew HG. *Rhinacanthus nasutus* improves the levels of liver carbohydrate, protein, glycogen, and liver markers in streptozotocin-induced diabetic rats. *Evidence-Based Complementary and Alternative Medicine*. 2013. doi:10.1155/2013/102901